

Migraine – An Incurable Disease?

Dr. med.dent. Paul Engel, 2560 Nidau (Switzerland)

Abstract

In this study 109 headache and migraine patients (82 women, 27 men) were questioned about their health status before and after removal of dental amalgam. These patients had all wished to have their amalgam dental fillings removed because of health problems. After completion of the treatment with different length of observation, 69% of them considered their health “much better”, 14% “better”, 10% “slightly better”, 7% reported “no improvement” of their health. No patient reported worsening of his health status.

Introduction

„One out of six persons in Switzerland suffers from migraine attacks. Many among them are incapable of working without medication. Migraine is still considered an incurable disease. Since a certain time, the cause has been suspected to lie in a genetic aberration. The day the responsible gene can be exactly localised, a durable therapy and even healing are conceivable.“

This was the summary of a medical TV programme on migraine broadcasted by Swiss TV in the beginning of April 2003. In fact, within the medical community, this is the most actual and widespread view concerning migraine.

Initially sharing the current opinion about migraine, I have changed my view on it totally. For almost ten years now, I have been working without amalgam dental fillings (“silver” tooth fillings) in my dentist’s practice. During this time, patients who had their dental amalgam removed confirmed to me repeatedly times as many patients have been attended by me. In the present new observational study, the effect of the removal of dental amalgam specially on migraine and headache is considered. These two symptoms were the most often mentioned ones before the removal of the fillings took place.

Results

In this new observational study, the migraine and headache patients from the above-mentioned investigation are included. The medical records from the years 1994 to 1998 were taken over and, if possible, updated, which was important also for the evaluation of the long-term effect. The records were completed with new cases from the years 1998 to 2003. In total, 109 patients, 82 female and 27 male, who had complained of migraine or headache before removal of their amalgam dental fillings, are being considered. These 109 patients are listed in the synoptic table in the appendix and being described there, more in detail, in short medical reports.

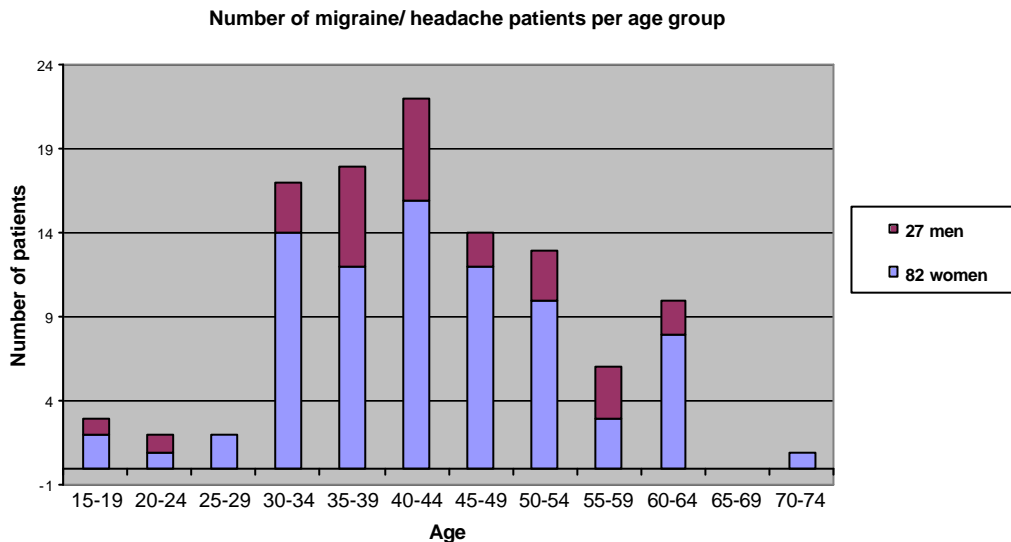
As stated in the former publication of 1998, migraine and headache were no isolated symptoms, but frequently occurred in combination with other symptoms.

Due to lack of space, however, in the synoptic table only the most frequently mentioned symptoms besides migraine and headache are listed.

The following symptoms were named mainly: Neck tensions (48 x), gastro-intestinal problems (37 x), dizziness (30 x), paraesthesia (22 x), back pain (17 x), exhaustion (15 x), psychic problems (15 x), impaired vision (15 x), allergies (14 x), joint pains (11 x), nasal/sinus problems (10 x), shoulder/arm problems (9 x), fatigue (9 x), rheumatism (6 x). The less commonly mentioned symptoms can be found in the medical records in the appendix.

Often the patients made an exact differentiation between migraine and headache. Sometimes only one of the symptoms was mentioned, sometimes both. Of the 109 migraine and headache patients, 69% considered their state of health “much better”, 14% “better”, 10% “slightly better”, while 7% found “no improvement” in their state of health after removal of the dental amalgam. None of the patients' health had deteriorated.

It is noteworthy that about three times more women than men complained of migraine and headache, an observation made also in the school medicine. In the following diagram, the patients are listed according to sex and age. The age at the moment of the removal of the first filling is indicated.



In the anamneses the time of onset of the symptoms had not been asked for. Therefore, this aspect is not considered in the diagram. It was remarkable, however, that women past 30 years of age suffering from migraine/ headache much more often asked for removal of their dental amalgam than other patients.

Material and methods

During the removal of dental amalgam, special protecting devices were always used:

1. Kofferdam (caulked by Oraseal for very sensitive patients),
2. Clean-Up aspirating system,
3. Patient respiration with oxygen
4. Factory-new hard metal drills to largely avoid heating during removal

When direct fillings of composit were made, underfillings of glasionomer cement (Vitrebond) showed to be very helpful. Since I have been using them, complaints about postoperative pains have diminished substantially.

Discussion

What is the reason why a patient with a lot of amalgam fillings does not suffer from migraine while another with only few fillings suffers from severe attacks? I think this question can only be answered considering the large disparity of sensitivity in different population groups. I refer to the diagram in my first publication of 1998 (1), which was taken from the “Kieler Amalgamgutachten” (expert’s report on amalgam) by Prof. O. Wassermann (2). This diagram shows the different sensitivities in a population group.

A simplified picture I often use when talking to migraine patients and patients with other forms of intoxication by amalgam is this one: In some areas, the nervous system seems to be “less well insulated”. Its reaction to a certain stimulus is much stronger than normally and the excitation lasts longer. As soon as the exposure to the toxic heavy metals can be reduced, the system slowly goes back to normality.

A second picture is the one of the overflowing poison-barrel: As soon as the individual level of heavy metals is lowered, the barrel does not overflow any more and the symptoms sometimes disappear in a relatively short time. Nevertheless they can reappear quickly when heavy metals or other toxins increase the burden of toxins in the body.

Two cases illustrate these pictures:

Patient No. 217 (SL, female) who, besides other symptoms, suffered from severe attacks of migraine, sensed a marked improvement of her health after removal of only a few of her amalgam fillings.

The headache of patient No. 49 (HR, female) disappeared after removal of the fillings. It gradually returned, however, after insertion of a metallic partial denture of chromium-cobalt-molybdenum. Her condition improved again only after she had been provided with a new partial denture free of metal.

In conformity with the study published in 1998 (1), migraine and headache again showed to often improve within a relatively short time after removal of the dental amalgam; in fact, they disappeared more rapidly than gastro-intestinal problems, joint pains or rheumatic disturbances. The suspicion arises that this may not only be due to the removal of the toxic mercury burden as such but also to the removal of metals in general with their specific physical properties. Anyhow it is conceivable that weak electric currents, generated by metals placed in the mouth, may have been of a certain importance in the health disturbances. Therefore, a possible reason for the sometimes very fast disappearance of migraine and headache could be that in most cases no more metals were used after amalgam removal, particularly also no gold-alloys.

In most cases the patients wanted composites only, to reduce the costs, even if the holes to be filled were large. If finances were not a decisive factor, metal-free inlays, crowns, and bridges made of plastics, ceramics or zirconium oxide were used.

It goes without saying that these observations leave many questions unanswered: How can the sometimes violent deterioration of the state of health immediately after removal of the amalgam fillings be explained? Were the protective measures for very weakened patients insufficient? Did patients, who at the same time underwent a detoxification therapy, experience a particularly drastic release of heavy metal from their deposits? Was the detoxification too intense (see e.g. Pat. No. 218, KC, female) or sometimes even inappropriate? Many successfully treated patients had followed no detoxification therapy at all.

Frequently, further symptoms together with migraine were noted and not uncommonly they disappeared as fast as the latter. Could these symptoms stand in connection with intoxication as well?

Should the neck tensions be interpreted as symptoms of intoxication of an especially susceptible group of muscles? Other diseases are well-known actually where toxins and neck muscle symptoms are in correlation (meningitis, tetanus).

To me the most important finding of this study lies in the fact that the sometimes impressive improvement of health after removal of amalgam persisted in most cases. The case with the longest period of observation dates back to the year 1989 (Pat. No. 73, VA, female).

A recently published paper from Sweden (3) produced similar results. Out of 463 patients more than 70% showed a persistent improvement of their overall health after removal of amalgam and other heavy metals.

Final remarks

Proponents of amalgam argue that amalgam cannot be an origin of migraine because this disease was already known in the Roman Empire. They should consider, however, that heavy metal intoxication has been attending mankind during centuries. Intoxications by lead were frequent in ancient times and there are similarities between intoxication by lead and by mercury.

Sceptics also often criticise studies which are based on questioning patients before and after amalgam removal, saying that they are unscientific as they rely on the subjective accounts rendered by patients.

The reply to this is that there simply exists no other method than to ask the patients, listen to them and believe them. In a scientific study the anamneses and catamneses (reports of efficacy of a therapy) of the patients would even have to have much more weight than it was possible in this paper to give them.

It is a special concern of modern research on migraine that this disease, which is difficult to understand for people unaffected by it, should be socially accepted. Efforts are being made to explain why migraine patients are not to be considered hypochondriacs with only imaginary symptoms, since the disease was shown to be due to a hypersensitivity of nerve cells in the central and autonomous nervous system. This could be proved with new scientific methods. Besides, the great individual disparities of forms of migraine in different patients are remarkable.

Migraine patients with credible anamneses assure that their attacks of migraine disappeared after removal of their dental amalgam, what does this mean? Migraine is a far too debilitating disease for a patient to talk of a crucial improvement or even healing if it has not really taken place.

A professor and well-known amalgam-specialist proposed to perform a study with a control-group. In the control-group migraine patients with amalgam dental fillings should be subsumed who refuse removal of their fillings. The comparison of the two groups would then provide evidence if the removal of dental amalgam really improves the health of the patients concerned.

For a dentist working in a private practice, the forming of such a control-group is not practicable, though, and furthermore senseless, for in reality this control-group already exists: It is the “group” of all the unsuccessfully treated migraine and headache patients who until today have never heard of the amalgam controversy.

Moreover, the following question may be allowed: Why is it not the university clinic itself that performs such an investigation with migraine patients, where the results seem to be specially obvious?

A long interview with a senior medical officer and well-known researcher into migraine was broadcasted by Swiss Radio in May 2003. He talked about established methods as well as

new ones concerning the diagnosis and therapy of migraine and also about the possible causes of this disease. He did not mention the terms amalgam or heavy metal, though.

It seems that heavy metal intoxication as a determining and serious factor for the release of migraine and headache is not an issue at university clinics. Or has amalgam, have all the heavy metals simply been underestimated in this connection?

The present article was written for my fellow-dentists and for other medical practitioners. May it incite them to include heavy metals and particularly amalgam in the search for the etiologic background of headache and migraine, two widespread diseases still considered incurable.

Literature

(1) Engel, P.: Beobachtungen über die Gesundheit vor und nach Amalgamentfernung (Health observations before and after amalgam removal), Schweiz Monatsschr Zahnmed, Vol 108: 8/1998 p 811-813; The English translation of the complete article can be read in:

www.amalgam-info.ch/engel.htm.

(2) Wassermann, O.: Kieler Amalgamgutachten 1997. This publication in German can be ordered from GZM, Seckenheimerstr. 11, 68239 Mannheim.

(3) Lindh U. et al.: Removal of dental amalgam and other metal alloys supported by antioxidant therapy alleviates symptoms and improves quality of life in patients with amalgam-associated ill health. Neuroendocrinol. Lett. 2002 Oct-Dez; 23(5-6): 459-82.

Acknowledgements

I am very indebted to Dr. Elisabeth Sulger-Büel and to Mr. Ruedi Scheurer for their careful English translation.

18 th August, 2003

Appendix

Medical Records of the 109 Migraine and Headache Patients

Patient No. 2 SM, male 1955

Headaches, neck tensions, impaired balance, night blindness, double vision (sometimes sees “double” road dividing lines), pressure in the eye, pulsation in the ear, peripheral vision flickering

12 DA (Dental Amalgams), 1st filling removed 12.92, last 9.93

6.96: no more dizziness, practically no more headaches, no more double vision, neck tensions 70% better

11.97: health improvement continuing

05.01: in good health

09.02: in good health

Own health assessment: **much better**

Patient No. 4 NU, female 1963

Constant sickness, dizziness, hearing problems, sudden weight loss and gain, susceptible to nasal and sinus infections, gynaecological problems, hair loss, joint pains, tinnitus, exhaustion, allergies, paraesthesias, severe **migraine**, severe **headaches**, has suffered from hepatitis, rheumatism, arthritis, agitation, severe depressions, digestive disorders

14 DA, 1st filling removed 6.95, last 5.96

5.96: considerable health improvement

7.97: health improvement continues, no more hair loss, no more joint pains, has reassumed work

4.98: health further improved, no comparison to the status before, psychically much stabler, no shyness any more, tinnitus better, hearing better, no joint pains or neck tensions any more, no more hair loss, no more exhaustion symptoms, work capacity 70% re-established (previously nearly complete work incapacity), continued gastro-intestinal disturbances and low blood pressure

5.03: no migraine or headache attacks any more. All symptoms disappeared with the exception of gastro-intestinal and liver disturbances with concomitant back pain

Own health assessment: **much better**

Patient No. 6 WH, female 1951

Neck tensions, very severe **headaches** starting from the neck and continuing „like a cold lightning“ into the head, pain like „holes in the head“, **migraine**, constant sickness, nausea, back pains, difficulties with equilibrium, eye pain during hours or days, ice-cold hands and feet, weakness and stiffness in knees and legs, tingling in extremities, metallic taste, gastro-intestinal disturbances, sensitive to weather changes, rheumatic pains, feeling down psychically, feelings of despair as no doctor can find cause, and the symptoms, therefore, are classified as “psychosomatic”, is even considered to be a case for psychiatry, which she denies, bad temper, aggressive, can no longer think properly, skull seems to “explode”, almost full work incapacity

15 DA, 1st filling removed 10.94, last 10.95

10.95: walks better, less weakness in legs

8.96: equilibrium much better, headaches improved, psychically much more motivated,

occasional tingling in the hands, no more stomach sourness, back pain better, no more nausea, no metallic taste anymore

10.97: work resumed as a janitor, is full of energy in the evenings, has not been feeling better in years, steady health improvement

7.98: further physical and psychic improvement, less depressive than before, “has a new life”

5.03: migraine-attacks rare compared to before, problems with arthrosis for 1 year.

Own health assessment: **much better**

Patient No. 7 RH, female 1952

Often **headaches** and **migraine** , sinusitis

15 DA, 1st filling removed 2.93, last 6.94

5.95: headaches much better

11.96: headaches with nausea connected with pylorus problems

2.98: in July 1997 in hospital due to severe infection with E.coli, continuing

gastro-intestinal disturbances, but far fewer headaches compared to before (last attack 5 weeks ago)

6.00:sinusitis left side and neuralgia persisting, problems with kidneys, but overall health clearly improved

3.02: no more headaches, health incomparable to before

Own health assessment: **much better**

Patient No. 8 KM, female 1946

very frequently strong **headaches**, problems with neck

14 DA, 1st filling removed 6.91, last 11.95

Severe headaches after each amalgam removal

1.96: still frequent headaches

3.97: ditto

3.98: headaches slightly better but neck problems still remain

7.00: ditto

3.01: still problems with digestion and joint pains

Own health assessment: **slightly better**

Patient No. 11 KG, male 1934

Very frequent, partially violent **migraine attacks**

11 DA, 1st filling removed 12.94, last 10.96

Already after removal of half of the fillings far fewer migraine-attacks

6.97: no more migraine attacks, nearly unbelievable to him, would never have thought that removal of DA could have such an effect on him

4.98: has had no migraine attacks for two years

7.01: no more migraine-attacks

9.02: ditto

Own health assessment: **much better**

Patient No. 12 RK, male 1943

Frequent **headaches**, **migraine** , gastro-intestinal disturbances

13 DA, 1st filling removed 12.93, last 11.96

12.93: piece of amalgam removed from former alveole, subsequently

fewer headaches so that patient wishes to have all fillings removed

11.96: headaches continue, but less severe and less frequent; digestion problems continue, but no more heartburn, overall health much better

2.98: feels much better, no headaches any more

12.00: lately weak headaches due to stress and warm wind but migraine totally gone

12.02: at most, weak headaches when the weather changes

Own health assessment: **much better**

Patient No. 13 VL, female 1937

Migraine

9 DA, 1st filling removed 6.95, last 10.95

7.96: migraine less frequent and less severe

11.97: migraine almost gone

4.01: success continuing

10.02: ditto

Own health assessment: **much better**

Patient No. 16 MM, female 1963

Migraine and **headaches** mainly before menstruation, dizziness, gastro-intestinal problems

6 DA, 1st filling removed 12.94, last 1.97

9.95: migraine, headache and dizziness gone

10.97: ditto

12.00: suffered from whiplash injury. Frequent migraine attacks again, in part paraesthesia in the hands

Own health assessment: **no improvement**

Patient No. 19 SD, female 1941

Headaches, migraine, allergies

12 DA, 1st filling removed 3.91, last 3.92

9.92: patient feels much better

7.95: Mamma Ca operation with ray therapy

1.97: practically no more headaches, no more migraine

1.98: since 12-97 headaches somewhat more frequent, thinks this is possibly caused by heavy medication, allergies better

12.00: had other, new health problems (because of Mamma Ca). Headaches definitely better

Own health assessment: **better**

Patient No. 23 RG, female 1949

Exhaustion, eye problems (double vision at the cinema, flickering), gastro-intestinal problems, **headaches, migraine**, neck tension, depressions

11 DA, 1st filling removed 6.93, last 8.97

8.97: continued gastro-intestinal problems, but health considerably better, no more neck tension, considerably less headache, no more eye problems, mental stability improved

4.98: gastro-intestinal problems much better, too, exhaustion gone, psychically much better

8.00: Heart operation (now prophylaxis against endocarditis necessary). Gastro-intestinal problems somewhat better

Own health assessment: **better**

Patient No. 24 DD, female 1934

Migraine originating from the neck, fibromyalgia, insomnia, depression, gastro-intestinal problems

13 DA, 1st filling removed 9.95, last 5.96

5.96: less headache and migraine, fewer depressions

11.96: headaches much better, less tired, insomnia improved, depressions much better

6.97: health much better except for gastro-intestinal problems

4.98: further health improvement, less tired, better sleep, no more heartburn, psychically much more stable

11.00: fibromyalgia improved, too, no more depressions, “simply in better form”, much fewer migraine attacks and headaches

3.03: health much better, no more depressions

Own health assessment: **much better**

Patient No. 25 TG, female 1950

Migraine, later impaired speech, partial paralysis

19 DA, 1st filling removed 9.95, last 5.96

1.97: less migraine

8.99: physician diagnosed MS

8.01: regularly little MS attacks

3.03: had a very good period without headaches and nearly without MS attacks for more than one year

5.03: had heavier migraine again

Own health assessment: **slightly better**

Patient No. 26 RU, female 1950

Dizziness, **headaches, migraine**, heart trouble (arrhythmias), paraesthesias in arms, gastro-intestinal problems, “internal nervousness”, penicillin allergy

9 DA, 1st filling removed 9.95, last 10.96
9.96: fewer headaches, fewer paraesthesias, less dizziness
11.96: gastro-intestinal disturbances better, too, less nervous
Own health assessment: **better**

Patient No. 27 TM, female 1957

Headaches, neck tensions, pain when lifting arm, hair combing impossible, back pain, neurological eye problems (ground appears to be closer than it is), dizziness, tremor in both hands, paraesthesias in hands, air in the stomach

10 DA, 1st filling removed 5.95, last 5.97
11.95: feels better, can move arm again, dizziness gone
3.96: dizziness gone, paraesthesias gone, no more pain, less stomach problems
1.98: practically all health problems have disappeared
6.98: no more back problems, can go camping with children
3.00: health much better, no more tremor, no more neck or arm problems, no more headaches
Own health assessment: **much better**

Patient No. 30 GR, male 1962

Headaches, back pain, skin allergy

11 DA, 1st filling removed 11.95, last 8.00
12.95: severe headache as a reaction to the removal of 3 fillings
8.97: far fewer headaches
9.97: severe reaction to the removal of another filling, decides to wait for fear of reaction to further amalgam removal
8.00: no headaches any more
4.03: has never been ill again, no headaches any more, skin allergy much better
Own health assessment: **much better**

Patient No. 33 KP, female 1932

Gastro-intestinal disturbances (colon). Stomach-ache continuing to the back and legs, joint problems mainly in fingers, nausea mainly in the morning, paraesthesias in legs and head, **migraine**, during the night “stitches in the head as from a sling”, ocular problems, joint problems, continuous restlessness

8 DA, 1st filling removed 11.95, last 6.96
6.96: no more stitches in the head, no more restlessness
11.96: much fewer paraesthesias, fewer gastro-intestinal disturbances
Own health assessment: **much better**

Patient No. 34 EG, male 1974

Allergies, extreme **headaches, migraine** with paralysis (can hardly walk, speak or hear any more), dizziness, ocular and auditory troubles, uses solvents (formaldehyde) at work

3 DA, fillings removed 2.96
2.96: migraine less frequent, less violent, severe headaches continue
9.96: less dizziness, migraine less severe and without paralysis
4.97: more frequent headaches and more dizziness again, but overall health improved
12.98: migraine much better, dizziness much better
Own health assessment: **much better**

Patient No. 35 BS, male 1957

Headaches, bad concentration, nose always stuffy (liquid secretion), sleep disturbances starting at 2 o'clock in the morning

10 DA, 1st filling removed 1.96, last 4.96
1.96: severe reaction after first amalgam removal
2.96: ditto
4.96: overall health much better, more energy, no headaches any more, less shoulder/arm pains, no

stuffed up nose any more
Own health assessment: **much better**

Patient No. 36 GK, male 1951

Migraine, strong **headaches**, unexplainable losses of consciousness since 1990 (which led to a frontal collision when driving)

9 DA, 1st filling removed 3.96, last 8.96

8.96: significantly fewer headaches

12.99: nearly no headaches any more

9.01: headaches only when the weather changes

Own health assessment: **much better**

Patient No. 41 MW, male 1940

Frequent, severe and enduring **migraine attacks**, dizziness, paraesthesias mainly in the arms, extreme vomiting spasms, back pains, neck tensions

7 DA, 1st filling removed 6.96, last 3.97

12.97: no migraine, paraesthesias or dizziness any more, feels “like new born”

6.98: no more migraine attacks ever, says that he feels much better psychically, too, neck tension and back pain have disappeared, feels “like 20” again

Own health assessment: **much better**

Patient No. 43 RC, female 1964

Strong **headaches**, frequent pharyngitis and laryngitis

3 DA, 1st filling removed 8.96, last 10.96

1.97: headaches less frequent but still severe, pharyngitis and laryngitis improved

Own health assessment: **slightly better**

Patient No. 45 CR, male 1942

Gastro-intestinal disturbances, **migraine**

18 DA, partly under crowns, 1st filling removed 8.96, last 1.97

1.97: no improvement

9.98: health much better

1.01: feeling “absolutely fine”

4.02: ditto

Own health assessment: **much better**

Patient No. 48 SJ, male 1948

Very frequent **headaches**, stomach trouble (acidity), skin problems, paraesthesias

15 DA, 1st filling removed 3.93, last 2.97

9.97: no more headaches or stomach problems

10.98: has never again had as severe headaches as before, sometimes stomach problems, but never as severe as before. In the past, he even had to vomit from the migraine attack

7.00: migraine much better than before

Own health assessment: **much better**

Patient No. 49 HR, female 1946

Headaches, migraine, dizziness, eye problems, paraesthesias in the hands, neck tensions, feels very uneasy

12 DA, 1st filling removed 12.93, last 2.97

4.97: health greatly improved, hardly any migraine

8.98: migraine practically gone, “difference like day and night”

2.00: no headaches at all any more, neck tensions better, no shoulder pain any more. Blood pressure normal and stable, overall health much better

4.03: more frequent headaches again. Has the impression that there is coherence with a metallic partial

denture fixed in march 02. Metallic taste. The headaches disappeared a few days after removal of the denture but came back when she had put it in again.

4.03: Setting in of a new, metal-free partial denture

5.03: headaches gone

Own health assessment: **much better**

Patient No. 50 SE, female 1953

Migraine, dizziness, tensions, undistinct strong pain in chest shoulder area, gastro-intestinal problems, tennis-ball- sized lump (“no doctor can tell me what it is”)

13 DA, 1st filling removed 9.96, last 6.97

11.96: gastro-intestinal problems much better, hardly any migraine any more

11.97: chest pains completely gone

7.98: further health recovery

1.00: migraine totally gone

5.01: ditto

1.03: ditto

Own health assessment: **much better**

Patient No. 54 TK, female 1947

Dizziness (diagnosed as Menière’s Disease), double vision, **migraine**, tooth 27 removed 7.92, less dizziness since then

9 DA, 1st filling removed 11.92, last 10.96

7.96: less dizziness

11.97: continued recovery, practically no more dizziness

7.00: dizziness gone, migraine gone

12.01: ditto

Own health assessment: **much better**

Patient No. 55 SH, female 1963

Migraine, sensitivity to light, pressure behind the eyes, nausea, gastro-intestinal problems, dizziness

14 DA, 1st filling removed 2.96, last 11.96

1.97: migraine much rarer, if such, then only as a headache. Digestive tract: can eat food that formerly did not agree with her.

Own health assessment: **much better**

Patient No. 58 SH, male 1937

Migraine, sometimes prickling in legs, tinnitus for 18 years

15 DA, 1st filling removed 5.95, last 10.96

1.96: migraine and paraesthesias considerably better, tinnitus persisting

1.98: ditto

6.02: ditto

Own health assessment: **better**

Patient No. 61 DC, female 1979

Has been having strong **migraine** with nausea for 1-2 years, 4 occlusal medium sized amalgam dental fillings set by us 8 years ago

4 DA, 1st filling removed 5.96, last 7.96

7.96: migraine weaker but still some dizziness

5.97: migraine and neck tension gone

Own health assessment: **much better**

Patient No. 68 HM, male 1960

Headaches, migraine, gastro-intestinal disturbances (Morbus Crohn?)

6 DA, 1st filling removed 6.96, last 1.97

2.97: no more migraine, far fewer headaches
2.98: last migraine attack in 12.97 (frequent attacks before), gastro-intestinal disturbances persist
6.00: had severe colitis, is well again by now
3.03: migraine gone
Own health assessment: **much better**

Patient No. 71 KJ, female 1935

Cardiac arrhythmias, paraesthesias in arms and legs, dizziness, **headaches**, strange sensation “as if part of the head moved away”.

4 DA, 1st filling removed 4.96, last 4.96
2.97: headaches gone, strange sensation gone altogether, paraesthesias gone
3.98: improvement continues
5.01: ditto
9.02: ditto
Own health assessment: **much better**

Patient No. 72 JN, female 1970

Sensitivity to light, ocular problems (cannot stand sunlight any more), back pains, partial paralysis (numbness, starting in little finger of right hand, then proceeding to elbow, left arm, shoulder, and finally knees), speech impairment, extreme loss of memory (after two minutes she forgot what she had eaten, or in what train she sat and in which direction it went), problems with neck muscles (needed her hands to push her bowed head back into normal position), dizziness, **migraine**

15 DA, 1st filling removed 9.95, last 5.96
3.96: less dizziness, no more speech impairment, less paralysis
4.96: severe reaction after amalgam removal (almost unable to move her arm)
5.96: repeated severe reaction after amalgam removal
7.96: no more paralysis in arms, short-term memory better, when tired still problems with finding words, still severe back pains, much less sensitive to light, fewer ocular troubles, less hay fever
3.97: overall health much better
3.98: health improvement continues (“lives again”)
Own health assessment: **much better**

Patient No. 73 VA, female 1943

“Buzzing” in the entire body, perceives slight trembling of entire body, dizziness, tensions in back, shoulder, and neck, **migraine**, heart arrhythmias
9 DA, 1st filling removed 5.89, last 4.95
9.91: less dizziness and fewer heart arrhythmias, migraine attacks shorter, “buzzing” in body completely gone
1.98: all symptoms almost totally gone, no more heart arrhythmias ever
12.00: ditto
5.03: all symptoms have disappeared durably
Own health assessment: **much better**

Remark: Mrs. V.A. was the very first patient who wished to have her DA removed in my practice for the sake of health. I agreed to do so although back in 1989, I could not believe yet that this measure would help in any way. But when after removal of the DA in other patients, they, too, experienced a change for the better in their health, I decided not to use amalgam any more from April 1994.

Patient No. 74 KH, female 1930

Dizziness (medical diagnosis: Menière’s Disease), muscle pain, **migraine**, nausea
13 DA, 1st filling removed 11.95, last 6.96
4.96: far less dizziness and nausea
4.97: steady health improvement
4.03: no more migraine, no dizziness, no stomach problems any more

Own health assessment: **much better**

Patient No. 75 JK, male 1937

Headaches (doctor believes they are due to problems of cervical vertebra), sensitivity to changes of weather

7 DA, 1st filling removed 7.95, last 6.97

5.97: no sensitivity to changes of weather any more, no more headaches, no more dizziness

7.00: no headaches any more, no dizziness, no sensitivity to changes of weather

Own health assessment: **much better**

Patient No. 77 FA, female 1957

Neck tensions, frequent **migraine** attacks, stomach problems, joint pains, hair loss, sinusitis

18 DA, 1st filling removed 6.95, last 8.97

8.97: much less migraine, overall health much better

6.01: somewhat more headache again, but not nearly as severe as before

Own health assessment: **better**

Patient No. 78 FM, female 1955

Neck tensions, back pain, **migraine**, **headaches**, gastro-intestinal problems, emotional problems

10 DA, 1st filling removed 3.97, last 10.97, possibly more amalgam under 4 crowns

10.97: overall health improved

1.98: migraine and neck tensions continue, gastro-intestinal problems better, depressions completely gone, general state of health distinctly better, less fog mentally, well-being as she has not experienced it for years

Own health assessment: **much better**

Patient No. 79 IC, female 1958

Persistent allergic rhinitis, neck tensions, **migraine**

6 DA, 1st filling removed 12.95, last 6.96

11.96: migraine continues with constant intensity, she believes it is closely connected with smoking

8.97: slightly less migraine, far fewer allergies, no more hay fever, neck somewhat improved

9.02: still some headaches, heavy smoker

Own health assessment: **slightly better**

Patient No. 80 MA, female 1938

Neck tensions, **migraine**, **headaches**

13 DA, 1st filling removed 3.95, last 6.96

9.97: migraine has disappeared, much less neck tension, only occasional headaches

7.98: further health improvement, no more neck problems (can park the car in the reverse gear again), very occasional headaches, no more lower back pain at all.

1.02: new health problem: Mamma-Ca operation, takes anticoagulants but migraine gone

Own health assessment (concerning migraine): **much better**

Patient No. 81 HM, female 1949

Chronic **headaches**, frequent numbness in right hand

15 DA, 1st filling removed 2.96, last 10.96

10.96: fewer paraesthesias in hand, far fewer headaches

1.98: headaches only during menstruation, much less numbness in hand, feels much better than formerly

3.99: ditto

Own health assessment: **much better**

Patient No. 88 RS, female 1963

Very strong hay fever, constantly biting sore throat, severe neck pain, shoulder pains (unable to carry handbag on shoulder), **migraine**, allergies

7 DA, 1st filling removed 1.95, last 7.96

7.96: no migraine any more, less neck tension

4.98: no neck tensions any more at all, no more migraine, no more hay fever for two years, no sore throat any more, no more shoulder problems

2.00: has taken no drugs at all for 1 year, no headaches any more, no neck tensions, no shoulder pain, allergy 90% gone (was extremely severe before)

Own health assessment: **much better**

Patient No. 93 DR, female 1944

Migraine (since the age of 14)

7 DA, 1st filling removed 2.99, last 3.01

11.99: no migraine any more

12.00: ditto, but new disease: herniated disc L3/4

3.01: had no migraine ever again

6.02:ditto

Own health assessment: **much better**

Patient No. 96 MS, female 1950

Severe **migraine**

14 DA, 1st filling removed 6.94, last 4.00

9.99: less migraine

2.00: not even headache during last month, not to speak of migraine

2.01: ditto

12.02: no migraine any more, sometimes a little bit headache

Own health assessment: **much better**

Patient No. 97 MJ, female 1961

Extreme fatigue, Epstein virus, immunological problems, doctor advised to remove DA, **headaches**, **migraine**, tinnitus, slight dizziness, chronic sinusitis (has the feeling that she has to breathe without using her nose as nose is always stopped up), problems with neck muscles, constipation, diarrhoea, candida

9 DA, 1st filling removed 7.00, last 9.00

9.00: migraine persisting

11.00: health better, sinusitis better, no dizziness any more, no more migraine

3.01: sinusitis totally gone

7.01: feels like “new-born”

6.02: fatigue much better, never again had a migraine attack, tinnitus much better, approximately 10% as compared to before

6.03 patient feels absolutely well, all chronic symptoms of illness except a very faint tinnitus have disappeared, can still not apprehend that the strong migraine which has been afflicting her since her youth, should be totally gone, never had to take drugs any more, feels like writing a book about her illness

Own health assessment: **much better**

Patient No. 100 RA, female 1936

Migraine, neck tensions

13 DA, 1st filling removed 8.99, last 4.00

5.00: headaches much better, only faintly sensible during weather changes, neck tensions nearly gone

2.03: health improvement persisting

Own health assessment: **much better**

Patient No. 101 BJ, male 1953

Severe **headaches** (doctor thinks they might come from the liver)

12 DA, 1st filling removed 8.00, last 12.00

12.00: severe headaches persisting
4.03: no improvement
Own health assessment: **no improvement**

Patient No. 102 DT, male 1966

Headaches, migraine (from right side zygomatic arch to forehead and neck), work inability, resistant to therapies, exhaustion, bruxism, neck tensions, back pains, rheumatic problems, extreme sweating, joint pains, emotional problems

9 DA, 1st filling removed 5.99, last 8.99

8.99: practically no migraine any more, no vomiting any more, intense sweating persisting

5.00: migraine much better, patient feels much better, rheumatic pains slightly better

2.01: sweating gone, too

3.01: migraine has come back

7.01: health much better again

8.02: headache gone, psychically much stabler

2.03: ditto

Own health assessment: **much better**

Patient No. 104 PR, male 1963

Heart arrhythmias, dizziness, in between **headaches**

13 DA, 1st filling removed 8.00, last 1.01

7.01: heart arrhythmias better, dizziness slightly better, headaches weaker, main problem at the moment: pain spreading out to left arm

Own health assessment: **slightly better**

Patient No. 107 DJ, female 1963

Gastro-intestinal problems (constipation, heartburn), **headaches**

16 DA, 1st filling removed 6.95, last 11.96

2.97: gastro-intestinal problems persisting

11.97: ditto

6.98: gastro-intestinal problems better, for 3 months constant headaches, neck problems, spine and back pain

9.99: headaches practically gone, stomach problems only in physical or psychic stress

9.01: stomach problems gone, headache nearly gone

Own health assessment: **much better**

Patient No. 110 DA, female 1958

Violent **migraine**, extreme fatigue, intestinal mycosis, allergy (skin), food allergies

12 DA, 1st filling removed 6.99, last 5.00

2.00: practically no migraine any more

7.00: migraine much better, no fatigue any more, skin allergy better, persisting only behind the ears, formerly also around eyes

Own health assessment: **much better**

Patient No. 113 GR, female 1960

Frequent **headaches**

6 DA, 1st filling removed 10.96, last 2.97

8.99: fewer headaches

3.03: headaches much better, enthusiastic

Own health assessment: **much better**

Patient No. 115 GH, female 1931

Had a cardiac infarction (1988), still suffering from heart asthma, when afraid has severe heart pains (Angina pectoris), **headaches**, hot feet at night, fidgety legs
11 DA, 1st filling removed 7.94, last 10.95
4.97: no headache any more, thinks that the extraction of tooth 26 might have had a positive effect, too
1.00: no headaches any more
8.00: never again had headaches, positive effect on Angina pectoris, too (less aggressive)
4.03: ditto
Own health assessment: **much better**

Patient No. 117 HA, female 1962

Intense joint pains, **migraine**, frequent influenza, neck problems, symptoms of severe exhaustion changing into depression, chronic sinusitis, trigeminal neuralgia (single incidence), sleep disorder
10 DA, 1st filling removed 12.99, last 5.00
5.00: nearly all symptoms totally gone, “new life”
Own health assessment: **much better**

Patient No.118 HC, female 1954

Symptoms of exhaustion, **migraine**, pain in the small of the back and the kidneys, sometimes neck problems, arthritis in the hands, conjunctivitis as soon as exposed to wind
13 DA, 1st filling removed 10.99, last 2.00
5.00: no improvement to be found as yet
Own health assessment: **no improvement**

Patient No. 119 HM, female 1962

Frequent **migraine** attacks, dizziness
10 DA, 1st filling removed 6.96, last 2.98
9.96: migraine already better
1.98: migraine much better
3.01: no dizziness any more, migraine gone
1.03: ditto
Own health assessment: **much better**

Patient No. 123 KR, female 1947

Frequent **headaches**, **migraine**, neck tensions, dizziness
13 DA, 1st filling removed 3.96, last 2.99
5.98: extremely heavy migraine attack after removal of last filling
11.98: strong reactions after each removal, but migraine better subsequently
2.00: no migraine any more
5.01: in good health
10.02: health improvement lasting
Own health assessment: **much better**

Patient No. 125 LB, female 1952

Migraine, vomiting, diarrhoea, sensitivity to noise and light, nausea very bad, experienced as worse than migraine
11 DA, 1st filling removed 4.00, last 9.00
8.00: no improvement, is undergoing a detoxification therapy
9.01: scarcely any improvement
4.03: no improvement, wants to have two crowns removed, too, which contain gold, hopes her situation will get better afterwards
Own health assessment: **no improvement**

Patient No. 128 MA, female 1954

Neck tensions, sometimes no sensitivity in hands and feet, inflammation of the iliosacral joint (at beginning of June cortisone injection there, since then slightly better, before pains from head to feet), symptoms of exhaustion, total feeling of illness, neck tensions: muscles like rubber bars, all hard and tense, **headaches, migraine** with aura, especially during menstruation

9 DA, 3 gold crowns with perhaps DA underneath, 1st filling removed 9.99, last 12.99

10.99: patient has 11 teeth with DA and gold crowns extracted, she wants a partial denture

1.00: no real migraine any more, just headaches, paraesthesias in hands and feet gone, nearly no pain in hips any more, but at the moment the muscles are still too weak there, health much better, much more energy (as she never had it for a long time)

5.01: no pains any more, for 2 months no migraine any more at all, no more problems during menstruation, can work during menstruation (was impossible before)

Own health assessment: **much better**

Patient No.130 MC, female 1965

Headaches, neck tensions, extremely many allergies (plaster, disinfectants, synthetic resins, penicillin, gold, medicaments)

12 DA, 1st filling removed 3.98, last 1.99

9.98: neck much better, headache persistent, but different from before

1.99: very severe headaches recently, but neck tensions much better

11.99: headache much better, neck tensions much better

2.01: headache considerably better

6.03: success persisting, no headaches any more, totally changed psychically, too, much more energy, less depressed

Own health assessment: **much better**

Patient No. 134 PR, female 1982

Frequent **headaches**

1 DA, removed 8.98

11.99: practically never headaches again

Own health assessment: **much better**

Patient No. 135 RS, female 1945

Migraine

15 DA, 1st filling removed 10.95, last 11.00

3.01: migraine has substantially diminished

Own health assessment: **better**

Patient No. 136 RU, female 1963

Symptoms of exhaustion, frequent **headaches**

10 DA, 1st filling removed 3.93, last 4.98

11.97: extremely frequent headaches after DA removal, was exhausted

6.98: headaches less severe and rarer than before, sooner gone, psychic status better, does not “fall into a hole” any more

3.00: headaches much better

Own health assessment: **much better**

Patient No. 140 ST, female 1951

Fatigue, back pain (pelvic obliquity), **headaches**, frequent sinusitis (maxillary sinus)

12 DA, 1st filling removed 7.97, last 12.99

8.97: first day after first DA removal severe headaches and migraine, second day sinusitis, third day pressure in the ear and diminished hearing during an entire week

8.97: severe headache again the day after removal, second day extreme sinusitis, then heavy pressure in the ears

3.98: extremely violent reaction after removal: heavy purulent sinusitis, severe headache during three weeks

5.98: back pain much better, no pelvic obliquity any more, beyond comparison with before, maxillary sinus better, headaches gone

8.98: ditto, less fatigue

11.99: never again had sinusitis, back pain much better, headaches gone, fatigue gone

11.00: ditto, headaches at the utmost when the weather changes

8.01: ditto

Own health assessment: **much better**

Patient No. 141 SM, female 1968

Migraine, rheumatism

10 DA, 1st filling removed 3.99, last 9.99

9.99: practically no headaches any more

9.00: better, but still headaches at times

10.01: migraine better but still relatively heavy back and shoulder pains

Own health assessment: **better**

Patient No. 142 SM, female 1965

Migraine, headaches, visual disturbances, dizziness, poor concentration, neck problems

13 DA, 1st filling removed 2.00, last 5.00

2.00: extremely tired after removal of first three DA but no headaches

3.00: dizziness after removal

5.00: head clearer, after last DA removal still migraine and visual problems, then never again, headaches much better, neck problems gone

5.01: health improvement persistent

Own health assessment: **much better**

Patient No. 144 SL, female 1945

Headaches

14 DA, 1st filling removed 6.96, last 8.99

8.99: headaches better but still occur when under stress

2.00: very rarely headaches

5.01: headaches somewhat worse than a year ago

Own health assessment: **better**

Patient No.147 SB, female 1962

Gastro-intestinal problems, severe **migraine** (daily to weekly), slight dizziness, formerly skin problems, low blood pressure

13 DA, 1st filling removed 7.97, last 8.00

9.99: migraine much better

8.00: never had migraine again

1.03: never had migraine again, feels in the best of health

Own health assessment: **much better**

Patient No. 149 SA, female 1967

Migraine

4 very small DA, 1st filling removed 9.97, last 10.97

11.02: still having migraine, patient thinks it could be due to anticonception pill

Own health assessment: **no improvement**

Patient No. 151 WM, female 1945

Headaches, hay fever, allergies

9 DA, 1st filling removed 3.95, last 5.99

3.98: headaches much better, wonders if allergy will be better in spring, too

5.99: never again had equally severe headache attacks, allergy lasted only until May instead of June, no eczemas, no pruritus any more

7.00: had hay fever during 3 months without eczema (in the past always severe eczemas on arms and chest with heavy pruritus), headaches very rare (once in two months), in the past always migraine, too, combined with heavy vomiting

1.03: incomparably better, only very rarely very weak migraine (in the past bedridden for days), no eczemas any more

Own health assessment: **much better**

Patient No. 154 HP, male 1959

Headaches

17 DA, 1st filling removed 10.97, last 8.00

2.99: practically no headaches any more although there are still 6 DA

8.00: headache at most when the weather changes but generally much less than before, takes no medicaments any more

5.03: some headaches only when the weather changes

Own health assessment: **much better**

Patient No. 157 RC, male 1952

Dizziness, **migraine**, **headaches**, neck problems, tinnitus, gastro-intestinal problems, paraesthesias in hands and feet, depressions, joint problems

8 DA, 1st filling removed 5.94, last 9.00

2.01: headaches slightly better, joint problems also

Own health assessment: **slightly better**

Patient No. 161 UB, male 1954

Migraine, neck problems, joint problems, shoulder problems, cannot go to sleep on his right side

2 DA, 1st filling removed 9.00, last 9.00

11.00: no improvement

12.02: migraine unchanged

Own health assessment: **no improvement**

Patient No. 164 CT, male 1986

Frequent severe **headaches**, **migraine** (referral from a physician for DA removal)

1 DA, removed 5.00

6.00: headaches and migraine much less frequent, less severe

7.01: telephone-call: patient has no headaches any more

1.03: had no migraine any more

Own health assessment: **much better**

Patient No. 169 MF, female 1951

CFS patient, symptoms of exhaustion, extreme fatigue, pains in upper arms, back pain, **headaches**, **migraine**

16 DA, 1st filling removed 5.99, last 12.00

2.00: fatigue slightly better, still strong pains in the back and upper arms

9.00: migraine less severe

12.00: migraine significantly less severe, back and upper arms well, new: fibromyalgia

5.01: migraine much better, fibromyalgia better, overall health better
Own health assessment: **much better**

Patient No. 173 SL, female 1945

Headaches, migraine, nausea, neck problems, back problems, hypersensitivity of the tongue
6 DA, 1st filling removed 9.00, last 3.01

3.01: headaches less frequent, migraine better, still back pain, neck problems, nausea, stomach problems persisting

10.01: slightly lesser headaches

Own health assessment: **slightly better**

Patient No.175 WM, female 1952

Headaches, neck tensions

18 DA, 1st filling removed 1.95, last 10.97

12.00: fewer neck tensions

Own health assessment: **slightly better**

Patient No.177 ZC, female 1976

Neck problems, eczemas on the entire body, gastro-intestinal problems, extreme paraesthesias in the feet, back problems, **migraine**, sinusitis of the maxillary sinus

3 DA, 1st filling removed 9.00, last 11.00

1.01: back more relaxed, no migraine any more, skin better (takes no cortisone tablets any more), digestive tract still bad, exhaustion persisting, paraesthesias in the feet better

7.01: enormous health improvement, only gastro-intestinal problems and sinusitis persisting, neck problems less severe, no paraesthesias any more, eczemas better, symptoms of exhaustion better, migraine completely gone

7.02: health improvement persisting

Own health assessment: **much better**

Patient No. 178 PA, female 1971

Panic attacks, breathing difficulties, joint pains, stomach troubles, **headaches**

9 DA, 1st filling removed 6.99, last 12.99

11.99: anxiety better, headaches better, stomach and joints unimproved yet

12.99: head symptoms all better, stomach and joints unimproved

Own health assessment: **better**

Patient No. 179 HP, female 1961

Gastro-intestinal problems (vomiting, diarrhoea), frequent **headaches, migraine**, fatigue

11 DA, 1st filling removed 12.98, last 1.01

5.99: frequent migraine

9.00: was almost constantly ill until last April, migraine significantly better

1.01: migraine significantly better

Own health assessment: **much better**

Patient No. 182 TH, female 1962

Migraine nearly every day, neck tensions, heart arrhythmias

10 DA, 1st filling removed 1.94, last 11.00

6.00: still frequently migraine and headaches

11.00: migraine only about once per month

1.01: migraine gone, weak headaches during influenza, neck tensions gone

Own health assessment: **much better**

Patient No.186 AD, male 1962

Prickling in the fingers, arm, face (paraesthesias in the corners of the mouth), weight loss, symptoms of exhaustion, hardened thigh muscles, **headache** behind the eye (“terrible pressure”), dizziness

17 DA, 1st filling removed 8.99, last 1.00

11.99: extreme reaction to detoxification therapy by a doctor (trembling hands, symptoms of exhaustion)

3.00: headaches practically gone, no cold hands any more, tremor much better

3.01: overall health much better, headaches when the weather changes, body weight gain from 56 to 68 kg, at sports not attaining 100% of the former performance yet

Own health assessment: **much better**

Patient No. 189 AY, female 1966

Exhaustion, pains particularly in the pelvis, exceptionally **migraine**, doctor refuses to continue treatment before patient has her DA removed

7 DA, 1st filling removed 12.99, last 2.00

2.01: feels in much better health, much less pain

Own health assessment: **much better**

Patient No. 195 GM, male 1952

Headaches, hay fever

14 DA, 1st filling removed 11.93, last 2.98

2.98: did not need his annual injection of depot cortisone any more last year, allergy better, headaches weaker

3.01: headaches less severe and rarer but still occurring at intervals

4.01: recently had another headache attack, allergy this year stronger again

Own health assessment: **slightly better**

Patient No. 198 SD, female 1962

Migraine, fatigue

7 DA, 1st filling removed 7.97, last 6.98

fellow-dentist had already removed half of her fillings, symptoms improved since then

5.98: had much headache and migraine again

9.99: last half-year practically no more headache, at most when the weather changes, fatigue persisting but less heavy than in the past

3.01: migraine very much better than before

Own health assessment: **much better**

Patient No. 199 MR, male 1971

Often **headaches**, **migraine**, bleeding in the vitreous body of both eyes

12 DA, 1st filling removed 4.01, last 6.02

6.02: no more migraine since last autumn

Own health assessment: **much better**

Patient No. 210 CI, female 1957

Allergies towards fruit and pollen, **headaches**, joint pains (back, fingers, hands), neck problems

17 DA, 1st filling removed 7.01, last 2.02

patient has 9 dead teeth which in part are a little sensitive

5.02: headaches slightly better, not so frequent any more but still rather severe

Own health assessment: **slightly better**

Patient No. 211 HH, female 1958

Problems in frontal and maxillary sinuses, neuralgia in legs and arms, constant **headaches**, stiff neck, symptoms of exhaustion

13 DA, 1st filling removed 9.00, last 1.01

8.01: headaches much better, symptoms of exhaustion much better, still some pain in arms and calves but overall health much better

5.03: overall health very much better

Own health assessment: **much better**

Patient No. 213 BJ, male 1958

Tinnitus, **headaches**, loss of memory, stomach-ache, heavy legs, has like a “black curtain” before his eyes (never in the past), pain behind sternum, chronic fatigue

10 DA, 1st filling removed 11.00, last 5.01

1.00: after last treatment depression, paraesthesia, eyes swimming, severe dizziness

3.01: more energy, tinnitus persisting, patient feels stronger, dizziness and depression gone

12.01: tinnitus unchanged, dizziness and stomach-ache gone, no headaches any more

9.02: tinnitus slightly better, chronic fatigue much better, all other symptoms much better

3.03: overall health much better, no exhaustion any more, “different as chalk from cheese”, tinnitus persisting

Own health assessment: **much better**

Patient No 217 SL, female 1948

Symptoms of exhaustion, cannot lie on her right shoulder any more, neck tensions, **migraine**, flatulence, paraesthesias in arms and legs, dizziness, nausea (mainly during the last three months), allergy towards penicillin and morphine, psychic disturbances, depressions, buzzing in the head, metallic taste, hearing and sight problems, extremely under stress, concentration problems (forgets names of persons she took pictures of), while talking no coordination between thinking and talking, confused answers (realises it instantly – as a child, she was best in class), eczemas

12 DA, 1st filling removed 1.02, last 8.02

2.02: feels much better already

6.02: after stopping Chlorella algae therapy she went through a crisis, many symptoms came back

2.03: all symptoms gone, patient feels healthy (detailed report on patient see in www.amalgam-info.ch/engel.htm under “a patient report”)

Own health assessment: **much better**

Patient No. 218 KC, female 1961

Symptoms of exhaustion, depression, severe **migraine**, problems with thyroid gland, 40 kg increase in weight, psychically unstable, paraesthesias, attacks of dizziness, back and knee pains

9 DA, 1st filling removed 2.01, last 4.02

2.02: extremely severe reaction to amalgam removal, gives the impression of drugging, does not remember where her car is parked, forgets what she said on the phone, has nightmares, buys dog’s food although she has no dog, total absent-mindedness during one week, loss of memory: did the same washing three times, has forgotten where she went to school, also many first and surnames

3.02: no migraine any more

4.02: never had migraine any more, as if a veil had been raised

8.02: had a dramatic relapse, even worse than in February, has even tried to commit suicide: an after-effect of the detoxification therapy? (Patient took 25 different drugs simultaneously)

3.03: Health much better again, has not taken most of her medicines any more, has more energy, depression sometimes worse, then much improved again, no migraine any more (in the past, three days per week confined to bed), no back and knee problems any more

Own health assessment: **much better**

Patient No. 220 RC, female 1962

Symptoms of exhaustion, very frequent **headaches** (from childhood), **migraine**, eczemas, metallic taste, sometimes does not endure light, dizziness, no energy, depressions mainly in winter, sensitive to noise, all

symptoms have inexplicably been increasing for the last 3 years, even if patient does not smoke and is an athlete, fitness was much better in the past, symptoms got worse mainly in head and face area
15 DA, 1st filling removed 4.02, last 7.02

4.03: practically no headaches any more, migraine gone, sensitivity to light and metallic taste gone, tendency to depressions gone (only three amalgam fillings left, out of financial reasons, patient wants to have them removed only in autumn)

Own health assessment: **much better**

Patient No. 231 BH, female 1941

Frequent **migraine**, back pain for 20 years, neck tensions, chronic fatigue, paraesthesias in arms starting with little and ring finger, now and then dizziness, joint pains (mainly shoulder joints), sometimes flickering in the eyes, hearing very bad on right side, hair loss, brash fingernails, had heart arrhythmias for a certain time, memory and concentration problems, metallic taste

8 DA, 1st filling removed 4.02, last 6.02

8.02: no migraine any more, back pain persisting

3.03: some more migraine anew, usually two days after acupuncture treatment, hopes that it will be better after end of treatment

Own health assessment: **better**

Patient No. 232 HM, female 1946

Diabetes for the last 6 years associated with faints and breakdowns, takes insulin now, feels slightly better, operation of the thyroid gland is planned, sleep disturbances, **headaches** mainly on the right side, diarrhoea and constipation

10 DA, 1st filling removed 9.02, last 1.03

2.03: headaches slightly better, not so frequent any more, neck tensions persisting

Own health assessment: **slightly better**

Patient No. 233 FJ, female 1968

Headaches, chronic sinusitis, allergies

6 DA, 1st filling removed 8.02, last 9.02

3.03: no headaches any more, no sinusitis either

Own health assessment: **much better**

Patient No. 234 SM, female 1954

Very frequent **headaches**, sometimes bordering on migraine, back pain, under pressure immediate lumbago, dizziness, neck problems, rarely paraesthesias in the arms, flickering in the eyes

15 DA, 1st filling removed 9.02, last 5.03

10.02: severe headaches after amalgam removal

5.03: no headaches any more, only when the weather changes; on a day like this, for instance, she should have headache, like her husband (who still has his DA), but she does not, so she says. This is a totally new and wonderful feeling; her overall health is much better

Own health assessment: **much better**

Patient No. 235 BM, female 1973

Stomach problems, faint depressions, some **headache**, slight back pains, neck tensions

2 DA, 1st filling removed 6.02, last 6.02

10.02: stomach problems persisting, neck tensions better, headaches slightly better

Own health assessment: **slightly better**

Patient No. 237 WU, female 1950

Metallic taste, circulation problems, sometimes tachycardia, frequent flickering in the eyes, as if eye had been rubbed for a long time, frequent **headache** starting in the left maxillary sinus and going up to the left eye, then changing into **migraine**, neck tensions, numb fingers (region of the finger-tips), pulse too high
8 DA, 1st filling removed 4.02, last 5.02

4.02: pulse normal again (came down from 125 to 65), headaches better, dizziness better, no flickering in the eyes any more

6.02: had severe headaches again

7.02: no circulation problems any more, neck tensions better, fingers not numb any more, headaches better, migraine weaker and rarer, dizziness markedly better, pulse good

Own health assessment: **better**

Patient No. 239 NS, female 1962

Conditions of total exhaustion, blood pressure too high, **migraine**, dull feeling in the head, difficulty of concentration, depressions, dizziness, draws a disability pension

9 DA, 1st filling removed 5.01, last 3.03

1.02: severe concentration problems, permanent pressure in the head, vomiting, colics

7.02: suffered from extreme dizziness and very strong headaches

1.03: migraine markedly better, also dizziness not as violent as before

3.03: no migraine any more during the last months, still heavy concentration problems

Own health assessment: **better**

Patient No. 241 RW, male 1942

Much pressure in the head, like **headache**, feeling of dullness, chronic fatigue, badly healing red flecks on arms and back of the hands which were intensively exposed to sunlight in the past

18 DA, 1st filling removed 4.02, last 4.03

5.03: Skin better, fatigue seemingly gone, feels generally much better, strange feeling in the head practically gone, patient wonders whether the following observation could also be attributed to the removal of the DA: only one year ago, after drinking relatively little alcohol (1-2 glasses of beer), he immediately felt a weak headache above the eyes, the next morning he always had headache when getting up while colleagues of his (with a comparable weight), who had drunk the same quantity, obviously felt nothing at all. These headaches are now totally gone, so he says, even when he drinks a little more alcohol

Own health assessment: **much better**

Patient No. 242 BL, female 1958

Migraine

8 DA, 1st filling removed 11.99, last 9.00

9.02: migraine still absolutely the same, no improvement at all

Own health assessment: **no improvement**

Patient No. 247 KJ, male 1952

Headaches, not very strong but regular, nervousness, tension

13 DA, 1st filling removed 3.02, last 12.02

3.03: fewer spreading out headaches

Own health assessment: **better**

Patient No. 251 HH, male 1954

Headaches, swollen legs, mainly on the left, pains originating in knee going as far as the hips, eczemas mainly on the left hand and left foot, recently more **headaches**, neck tensions, flatulence, chronic fatigue, loss of appetite, cramps in the region of the ribs, chronic cough, insomnia

7 DA, 1st filling removed 12.02, last 2.03

1.03: no headaches any more, legs less heavy, eczema of the hand better

2.03: sleep much better, fatigue better, eczemas clearly better, no heavy legs any more, stomach cramps gone, no headaches any more
Own health assessment: **much better**

Patient No. 253 SG, female 1951

Very frequent **migraine**

15 DA, 1st filling removed 6.95, last 12.01

5.03: only very rarely very weak migraine, in no case as strong as before, one tablet is sufficient to stop it

Own health assessment: **much better**

Patient No. 256 SR, female 1947

Very frequent **headaches**

8 DA, 1st filling removed 9.00, last 11.01

3.03: fewer headaches

Own health assessment: **better**

Patient No. 257 MS, female 1943

Allergies (cow-milk, dairy products, feline hair, food preservatives, indoor dust), chronic cold in the head, asthma, **headaches, migraine**

3 DA, 1st filling removed 5.96, last 7.96

12.96: colds better, headaches and migraine persisting

12.99: allergies better, no asthma any more, migraine much better

3.00: no allergies any more (medication stopped), migraine much better, asthma gone, sometimes still cough

3.03: headaches only every now and then, no migraine any more, no allergies any more

Own health assessment: **much better**

Patient No. 258 PM, female 1934

Headaches, neck problems

8 DA, 1st filling removed 8.97, last 4.03, two titanium implants 14 und 15

4.03: no improvement as yet

Own health assessment: **no improvement**

Patient No. 261 CI, female 1964

Chronic fatigue, fibromyalgia, **migraine**, very frequent **headaches**, neck problems, paraesthesias in the hands, joint pains (ankle, knee), sees black points, symptoms of exhaustion

10 DA, 1st filling removed (at a fellow-dentist's) 5.02, last 5.03

5.03: headaches have been decreasing by 90% since one year (in the past got up with headaches and went to bed with headaches), fatigue much better, paraesthesias gone

Own health assessment: **much better**