

Health Observations Before and After Amalgam Removal *

Dr.med.dent. Paul Engel
Lyss-Strasse 24, 2560 Nidau
Switzerland

Introduction

From 1972-1993 (5 years internship and 16 years of my own practice) amalgam was by far the most prevalent dental filling material used by me (in the side tooth area). Different reasons led me to abandon use of this material in the spring of 1994. An amalgam-critical work which had appeared in the FASEB journal in 1989 (Hahn et al.) was certainly an important reason for my decision. Moreover, some of my own earlier observations (e.g. with Pat. No. 2 and Pat. No. 73) and the fact that alternatives to amalgam were widely available, were equally important reasons for me to discontinue using amalgam, a material I had considered highly reliable before.

From the 1800 patients whom I had treated in the last four years, roughly 90 wished to have their partially intact amalgam fillings - often done by me - replaced by another material (mostly composites and compomere). Predominantly, these were patients with certain health problems, who had been influenced by an acquaintance or via different media and had learned of the possible toxic effect of mercury from amalgam.

On the one hand, I wanted to find out which symptoms existed before amalgam removal had taken place. On the other hand, I wanted to record health modifications which patients had described after the removal.

Results

In the table 1, symptoms indicated by the patients were listed. Qualitative health improvements were described in each case with the terms "much better", "better", "somewhat better", "no improvement", "worsening". In the diagram wider below, gender and age distribution of patients are differentiated.

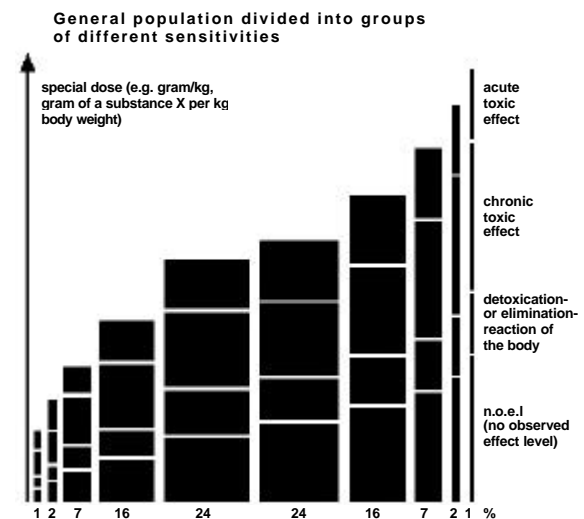
Discussion

52 women and 23 men (i.e. approx. 4% of the patients treated by me in the last 4 years), mostly over 30 years old, complained of chronic symptoms such as migraine (36x), headache (32x), gastro-intestinal disturbances (27x), neck tension (25x), paraesthesia (19x), dizziness

(18x), allergies (13x), vision disturbances (13x), back pain (12x), mental disorder (12x), joint pain (10x) and shoulder/arm pain (10x). After removing the amalgam, 68% of the patients believed their health had become "much better", 12% "better", 9% "somewhat better", 7% had experienced "no improvement" whatsoever, and 1% "worsening".

Certainly this is an amazing, almost unbelievable result. Had the patients or had the dentist embellished the results? I do not believe this.

Do the patients described belong to a particularly "amalgam-sensitive" group? On the following graph, based on the "Kieler Amalgam-Gutachten 1997", the distribution of the differently sensitive groups of a population is represented:



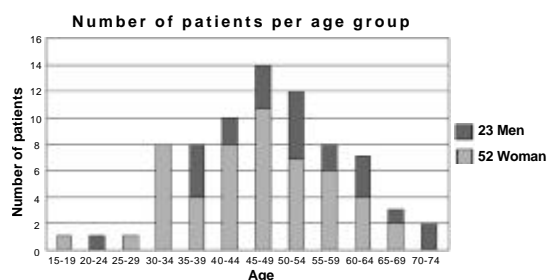
Whereas a large majority of the population feel little or no disease characteristics during a certain toxic agent impact, those 10% at the lefthand side of the graph already display acute-toxic symptoms.

I do not know whether the large part of the 75 patients described can belong only to such a particularly mercury-sensitive group. Connected with this is also the question of the importance of the estimated number of unknown cases. For example, Patient No. 41 had been treated by me for many years without ever once mentioning that he had constantly suffered from severe migraine. How many undiscovered patients with similar health problems as described above could be among the other patients of mine?

On the following diagram, the age specification is related to the year 1997. No conclusions can be made concerning the actual beginning of the symptoms. Why did more than twice as many

Health Observations Before and After Amalgam Removal

women than men have their amalgam fillings removed? Are they more sensitive at a certain age than men to amalgam questions or are they simply more often ill than men?



Conclusion

Certainly it will be necessary to pursue further investigations and to observe health modifications with the patients who have already been examined. Will their health continue to improve? Henceforth, in any case, I will pay more attention in future to the health modifications after amalgam removal than before. Patients would have to be asked more systematically about the time frame of the origin of their disease and its development as well as the point in time when amalgam removal was undertaken. Above all, however - and that is probably the main purpose of this work - I would like to know whether other colleagues have made any similar observations.

General methodical observations

In order to protect the patient - and the dentist - from mercury vapor, the "Clean Up" suction system (Scania Dental AB Sweden) was used. This allows mercury vapor in a patient's mouth to be reduced by a factor 100. The rubber dam was sealed with "Oraseal" (Ultradent Products). As filling material, composites (direct fillings and inlays) and also compomere were applied. In general, two fillings per session were replaced. Despite preventive measures, some particularly sensitive patients reacted strongly to the amalgam removal (e.g. Pat. No. 30, 29,72) with a temporary aggravation of their symptoms. In such cases, a longer break of about a month between the individual sessions had to be allowed for.

Empirical data of 75 patients

Usually the patients appeared after one year for "recall". Their state of health was always inquired about. The last statements were attached to the table. It was interesting that sometimes together with other positive feedback, disappearing symptoms were referred which had not ever been mentioned before. This concerned above all "neck tension", which was noticeable to

me only after many recalls. And also the improvement of symptoms such as "mental problems", "fatigue", "concentration difficulties", and "memory problems" were often only mentioned explicitly afterwards by patients.

It was remarkable how often symptoms such as "headache" and (above all) "migraine" had substantially improved or even completely disappeared even before all the amalgam fillings had been removed.

Even the complete disappearance of a very strong neurodermatitis (Pat. No. 63), i.e. a symptom which nobody else had ever mentioned, was indeed impressive.

Just as amazing was the disappearance of shoulder / arm pain (e.g. Pat. No. 20, 69, 67, 50, 27) persisting for many years, which had completely disappeared. Something similar can be reported also with the "allergies" (e.g. Pat. No. 37).

Whereas the symptoms of "migraine", "dizziness", "neck tension", "sight impairment" and "paraesthesia" improved seemingly fast or even totally disappeared after amalgam removal, this did not seem to be the case with patients suffering from "stomach / intestine" disorder symptoms.

Finally, a significant improvement could be observed in one case (Pat. No. 17) with "MS" diagnosis.

Literature

L.J. Hahn, R. Kloiber, M.J. Vimy, Y. Takahashi, and F.L. Lorscheider: "Dental "silver" tooth fillings: A source of mercury exposure revealed by whole body image scan and tissue analysis". FASEB journal 2640 vol. 3 Dec. 1989.

Kieler Amalgam-Gutachten 1997, available from GZM, Seckenheimerstr.111, 68239 Mannheim.

* English translation of "Beobachtungen über die Gesundheit vor und nach Amalgamentfernung", Schweiz. Monatsschr. f. Zahnmed. (Vol. 108: 8/1998), by S. Dott.

Health Observations Before and After Amalgam Removal

Patient initials	Patient number	Birthdate	Women	Men	Number of amalgam fillings	First amalgam removal	Last amalgam removal	Before amalgam removal, 52 female																									
								Sensitive to weather changes	Muscle atrophy	Whiplash injury	Sensitivity to electromagnetic fields	Neurodermatitis	Immune system problems	Lymphnode swelling	Dizziness	Circulation problems	Low blood pressure	Articular pain	Neck tension	Vestibular disorders	Disturbances of vision	Weight loss	Tinnitus	Headache	Migraine	Asthma	Allergic rhinitis	Paraesthesia	Allergies	Gastro-intestinal disturbance			
			52	23	811			2	1	1	2	1	2	18	3	5	10	25	3	13	2	3	32	36	2	4	19	13	27				
B.C.	28	1948	1		16	10.95	3.96										1												1	1			
B.R.	5	1964	1		12	6.95	8.95																										
B.S.	35	1957		1	10	1.96	4.96																	1									
C.R.	45	1942		1	18	8.96	1.97																		1						1		
D.C.	61	1979	1		4	5.96	7.96							1				1							1								
D.D.	24	1934	1		13	9.95	5.96																	1	1						1		
E.C.	64	1946	1		8	10.96	3.97							1		1																	
E.G.	34	1974		1	3	11.95	2.96																	1	1						1		
F.A.	77	1957	1		18	6.95	8.97																	1	1						1		
F.M.	15	1949	1		10	1.95	11.95																										
F.M.	78	1955	1		10	3.97	10.97																		1	1						1	
G.E.	82	1925		1	17	3.96	1.98																									1	
G.H.	44	1960		1	10	9.96	1.97																										
G.K.	36	1951		1	9	3.96	8.96																		1	1							
G.R.	30	1962		1	11	11.95																										1	
H.A.	66	1946		1	12	11.95	3.96																										
H.H.	3	1951		1	13	9.85	4.86																										
H.H.	37	1944		1	12	1.94	12.95																										
H.M.	42	1962	1		10	4.96	1.98																										
H.M.	68	1960		1	6	6.96	1.97																		1	1							1
H.M.	81	1949	1		15	2.96	10.96																										
H.R.	49	1946	1		12	12.93	2.97																										
H.S.	60	1943	1		6	7.94	6.96																										
I.C.	79	1958	1		6	12.95	6.96																										
J.F.	63	1956	1		11	12.95	3.96																										
J.K.	75	1937		1	7	7.95	6.97																										
J.N.	72	1970	1		15	9.95	5.96																										
K.B.	76	1960	1		7	8.95	6.97																										
K.E.	69	1952	1		15	9.96	11.96																										
K.G.	11	1934		1	11	12.94	10.96																										
K.H.	74	1930	1		13	11.95	6.96																										
K.J.	71	1935	1		4	4.96	4.96																										
K.M.	8	1946	1		14	6.91	11.95																										
K.P.	33	1932	1		8	11.95	6.96																										
M.A.	80	1938	1		13	3.95	6.96																										
M.C.	85	1958	1		17	2.96	7.97																										
M.H.	67	1940	1		6	7.87	7.87																										
M.J.	14	1963	1		16	6.95	11.96																										
M.M.	86	1938	1		13	8.92	1.93																										
M.M.	16	1963	1		6	12.94	1.97																										
M.S.	51	1943	1		3	5.96	7.96																										
M.S.	57	1958	1		12	5.96	6.97																										
M.W.	41	1940		1	7	6.96	3.97																										
N.P.	31	1960		1	9	11.95	3.96																										
N.U.	4	1963	1		14	6.95	5.96																										
P.T.	17	1948	1		10	95	96																										
R.C.	43	1964	1		3	8.96	10.96																										
R.G.	23	1949	1		11	6.93	8.97																										
R.H.	7	1952	1		15	2.93	6.94																										
R.K.	12	1943		1	13	12.93	11.96																										
R.M.	1	1954	1		13	5.93	5.94																										
R.S.	88	1963	1		7	1.95	7.96																										
R.U.	26	1950	1		9	9.95	10.96																										
S.A.	87	1967	1		4	7.97	9.97																										
S.D.	19	1941	1		12	3.91	3.92																										
S.E.	50	1953	1		13	9.96	6.97																										
S.E.	52	1941	1		5	3.96	7.96																										
S.F.	9	1957	1		12	1.92	7.96																										
S.H.	55	1963	1		14	2.96	11.96																										
S.H.	58	1937		1	15	5.95	10.96																										
S.J.	48	1948		1	15	3.93	2.97																										
S.M.	21	1950	1		16	5.95	12.95																										
S.M.	2	1955		1	12	12.92	9.93																										
S.W.	46	1924		1	10	6.96	1.97																										
T.G.	25	1950	1		19	9.95	5.96																										
T.K.	54	1947	1		9	11.92	10.96																										
T.M.	27	1957	1		10	5.95	5.97																										
V.A.	73	1943	1		9	5.89	4.95																										
V.J.	59	1944		1	5	6.96	12.96																										
V.L.	13	1937	1		9	6.95	10.95																										
W.H.	6	1951	1		15	10.94	10.95																										
W.L.	53	1936	1		10	5.96	9.96																										
W.R.	65	1943		1	9	1.97	4.97</																										

Empirical data of 75 patients

Patient No. 1 R.M., male 1954

symptoms: dizziness, low blood pressure, joint pains
13 amalgams, 1st filling removed 5.93, last 5.94
11.96: practically no dizziness left, stable blood pressure
2.98: all mentioned symptoms in order
own health assessment: much better

Patient No. 2 S.M., male 1955

symptoms: headaches, neck pains, balance impaired, night blindness,
double vision (sometimes sees “double” road dividing lines), peripheral vision flickering
12 amalgams, 1st filling removed 12.92, last 9.93
6.96: no more dizziness, occasional headaches, no double vision,
neck pains 70% better
11.97: continuing health improvement
own health assessment: much better

Patient No. 3 H.H., male 1951

symptoms: acute joint pain, “tennis elbow” related pain, forced to abandon
career as a carpenter
13 amalgams, 1st filling removed 9.85, last 4.86
6.97: health improved with less pain
own health assessment: better

Patient No. 4 N.U., female 1963

symptoms: constant sickness, dizziness, hearing problems, sudden weight loss
and gain, frequent nasal and sinus infections, gynecological problems, hair loss, joint pain,
exhaustion, allergies, paraesthesia
14 amalgams, 1st filling removed 6.95, last 5.96
5.96: considerable health improvement
7.97: health still improved, no hair loss, no joint pain, work reassumed
4.98: health improvement, psychic stability, decrease in shyness, tinnitus better, hearing better, no
more joint or neck pain, no more exhaustion symptoms, 70% work capacity (previously near complete
work incapacity), continued gastro-intestinal disturbances and low blood pressure
own health assessment: much better

Patient No. 5 B.R., female 1964

symptoms: MS, numbness in lower body, difficulties with equilibrium
12 amalgams, 1st filling removed 6.95, last 8.95
5.96: no improvement
5.97: no improvement
9.97: deterioration of symptoms
own health assessment: worsening

Patient No. 6 W.H., female 1951

symptoms: neck tension, sudden severe headaches from the neck to the head, head pains like
“lightning flashes”, migraines, repeated feeling of sickness, extreme nausea, back pains, difficulties
with equilibrium, day and night eye pain, ice-cold hands and feet, weakness and stiffness in knees
and legs, tingling in extremities, taste of metal, gastro-intestinal disturbances, sensitive to weather
changes, rheumatismal pains, feeling down mentally, feelings of despair (no organic causes found
medically, therefore assigned as “psychosomatic” although the patient feels this is not the case), can
no longer think properly, skull seems to “explode”, almost fully work impaired
15 amalgams, 1st filling removed 10.94, last 10.95
10.95: walks better, less weakness in legs

Health Observations Before and After Amalgam Removal

8.96: equilibrium much better, headaches improved, psychically much more motivated, occasional tingling in hands, no more stomach sourness, no more nausea
10.97: janitorial work resumed, back pain improved, no more uneasiness, has not been feeling better in years, steady health improvement
7.98: further corporal and psychic improvement, less depressive than before, "has a new life"
own health assessment: much better

Patient No. 7 R.H., female 1952

symptoms: numerous headaches and migraine, sinus infections
15 amalgams, 1st filling removed 2.93, last 6.94
5.95: headaches much better
11.96: headaches with nausea connected to pylorus problems
2.98: in July 1997 hospitalized due to severe colon infection, continuing gastro-intestinal disturbances, compared to before far fewer headaches (last 5 weeks)
own health assessment: better

Patient No. 8 K.M., female 1946

Symptoms: often strong headaches, neck problems
14 amalgams, 1st filling removed 6.91, last 11.95
severe headaches after each amalgam removal
1.96: still numerous headaches
3.97: same
3.98: headaches somewhat better, but neck problems still remain
own health assessment: somewhat better

Patient No. 9 S.F., female 1957

symptoms: migraine
12 amalgams, 1st filling removed 1.92, last 7.96
10.96: practically no more migraine
7.97: same
own health assessment: much better

Patient No. 11 K.G., male 1934

symptoms: severe, recurrent migraine
11 amalgams, 1st filling removed 12.94, last 10.96
already after removal of half the fillings far fewer migraines
6.97: no more migraine
4.98: no more migraine for two years
own health assessment: much better

Patient No. 12 R.K., male 1943

symptoms: frequent headaches, gastro-intestinal disturbances
13 amalgams, 1st filling removed 12.93, last 11.96
12.93: piece of amalgam removed from former alveole
due to fewer headaches, patient wishes to have all fillings removed
11.96: headaches continue, but less severe and often digestion problems continue, but no more acid stomach
2.98: feels much better, no more headaches
own health assessment: much better

Patient No. 13 V.L., female 1937

symptoms: migraine
9 amalgams, 1st filling removed 6.95, last 10.95
7.96: migraine less often and less severe
11.97: migraine almost gone

Health Observations Before and After Amalgam Removal

own health assessment: much better

Patient No. 14 M.J., female 1963

symptoms: stomach / intestinal problems
16 amalgams, 1st filling removed 6.95, last 11.96
11.97: intestines much better, stomach still bad
own health assessment: somewhat better

Patient No. 15 F.M., female 1949

symptoms: strong pains in arm, can hardly move it, not even shake hands, diagnosis unclear (doctor believes possibly neuritis or rheumatic arthritis), can hardly go upright anymore, overall painful tensions in back and neck.
10 amalgams, 1st filling removed 1.95, last 11.95
12.96: fewer and arm pains
5.97: fewer pains, use of hands returns
1.98: all pain fully gone, plays the piano again
own health assessment: much better

Patient No. 16 M.M., female 1963

symptoms: migraine and headaches before menstruation, dizziness, gastro-intestinal disturbances
6 amalgams, 1st filling removed 12.94, last 1.97
9.95: migraine, headache and dizziness gone
10.97: same
own health assessment: much better

Patient No. 17 P.T., female 1948

symptoms: MS, 7 years before neuritis on optical nerve (first colors perceived wrong then in periphery opaque spots, improved after 5 months of cortisone treatment, MS diagnosis made by lumbar puncture, different sensitivity to heat in hands, feelings of having a “spiderweb” in her head, physical effort accompanied by an “electric shock” from head to toes (“coup de l’ermite”), headaches, migraine
10 amalgams, fillings removed from 1995-6
1.98: paraesthesia completely disappeared, current neurologist doubts previous MS diagnosis, fewer headaches and migraine
own health assessment: much better

Patient No. 19 S.D., female 1941

symptoms: headaches, migraine, allergies
12 amalgams, 1st filling removed 3.91, last 3.92
9.92: patient feels much better healthwise
7.95: Mamma Ca operation with radiation
1.97: practically no more headaches, no more migraine
1.98: since 12-97 headaches a bit more often, possibly caused by heavy medication, allergies better
own health assessment: much better

Patient No. 20 Z.E., male 1929

symptoms: hip and hernia pain, unaccountable shoulder / arm pains (muscle inflammation), cannot lift arm, no strength in arm, stomach problems
12 amalgams, 1st filling removed 7.95, last 2.96
12.95: fewer pains, cortisone discontinued
7.96: no more shoulder problems
10.97: same, full strength regained in shoulder
own health assessment: much better

Patient No. 21 S.M., female 1950

symptoms: neck tension, arthritis in fingers, paraesthesia
16 amalgams, 1st filling removed 5.95, last 12.95
12.95: no more arthritis in fingers, slight neck tension
7.96: no more arthritis, paraesthesia
7.97: steady improvement
own health assessment: much better

Patient No. 23 R.G., female 1949

symptoms: exhaustion, eye problems (double vision at cinema, flickering), stomach / intestinal problems, migraine, neck tension, depression
11 amalgams, 1st filling removed 6.93, last 8.97
8.97: continued gastro-intestinal disturbances, health considerably better, no more neck tension, considerably less headaches, no more eye problems, mental stability
4.98: stomach / intestinal problems better, exhaustion disappeared, mental improvement
own health assessment: much better

Patient No. 24 D.D., female 1934

symptoms: migraine originating in the neck, rheumatism, insomnia, depression, stomach / intestinal problems
13 amalgams, 1st filling removed 9.95, last 5.96
5.96: fewer headaches and migraine, less depression
11.96: headaches much better, less tired, insomnia improved, depression much better
6.97: health much better except for gastro-intestinal disturbances
4.98: further health improvement, less tired, better sleep, no more stomach burning, mentally more stable
own health assessment: much better

Patient No. 25 T.G., female 1950

symptoms: migraine, speech impaired, partial paralysis
19 amalgams, 1st filling removed 9.95, last 5.96
1.97: far fewer migraines
own health assessment: much better

Patient No. 26 R.U., female 1950

symptoms: dizziness, headaches, migraine, heart trouble (arrhythmia), paraesthesia in arms, stomach /intestinal problems, "inner nervousness", penicillin allergy
9 amalgams, 1st filling removed 9.95, last 10.96
9.96: fewer headaches, less paraesthesia, less dizziness
11.96: gastro-intestinal disturbances, less nervous
own health assessment: much better

Patient No. 27 T.M., female 1957

symptoms: neck tension, pain when lifting arm, hair combing impossible, back pain, neurological eye problems (ground or floor appear closer than in reality), dizziness, hand trembling, paraesthesia in hands, flatulence
10 amalgams, 1st filling removed 9.95, last 5.97
11.95: Healthwise better, ability to move arm, dizziness gone
3.96: dizziness gone, paraesthesia disappeared, no more pain, less stomach problems
1.98: practically all health-related problems gone
6.98: no more back problems, can go camping with children
own health assessment: much better

Patient No. 28 B.C., female 1948

symptoms: paraesthesia mostly in hands, frequently severe sore throat, tiredness, joint pain,

Health Observations Before and After Amalgam Removal

digestion disorder

16 amalgams, 1st filling removed 10.95, last 3.96 (titanium implant 47 removed)

11.96: continued throat pains, fewer joint aches, continued digestion problems (diarrhea, gas)
continued paraesthesia in hands as well as feet

4.98: continued joint pain, hardly better than a year before

own health assessment: somewhat better

Patient No. 29 Z.K., female 1957

symptoms: stomach / intestinal problems, joint complications (rheumatic inflammation in iliosacral region), numerous sore throats, weight gain, very large lymph nodes, frequent earaches, multiple allergies, severe back problems for 6 years, previously very fit, very low blood pressure, psychic problems, continuous feeling of sickness

13 amalgams, 1st filling removed 2.96, still 4 fillings undone

3.96: health deterioration after amalgam removal

11.96 and 1.97: repeated serious reaction to amalgam removal, wishes to wait for the removal of the last 4 amalgams, fear of recurring reaction

4.98: decision to have the four remaining fillings removed

own health assessment: no assessment

Patient No. 30 G.R., male 1962

symptoms: headaches, back pains

11 amalgams, 1st filling removed 11.95, still 5 fillings undone

12.95: severe headache reaction to the removal of 3 fillings

8.97: far fewer headaches

9.97: repeated severe reaction to the removal of another filling, decides to wait in fear of a renewed reaction to an amalgam removal

Patient No. 31 N.P., male 1960

symptoms: sight impairment, larynx pains, skin rash, acute diarrhea, insomnia, neck tension, migraine, paraesthesia, memory disorder

9 amalgams, 1st filling removed 11.95, last 3.96

10.96: no more depression after 2-3 months of single treatment, after filling removal no more headaches, larynx pains gone, skin rash gone, vision disturbances still equally strong, insomnia improvement, continued migraine but less frequent, paraesthesia gone, memory still irregular

own health assessment: somewhat better

Patient No. 33 K.P., female 1932

symptoms: gastro-intestinal disturbances (colon) . stomach to back pains leading to leg pain, joint problems in fingers, nausea in the morning, paraesthesia in legs and head, nightly shooting pains in head, ocular problems, joint problems, continuous uneasiness

8 amalgams, 1st filling removed 11.95, last 6.96

6.96: no more head throbs or uneasiness

11.96: much less paraesthesia, fewer gastro-intestinal disturbances

own health assessment: much better

Patient No. 34 E.G., male 1974

symptoms: allergies, severe headaches, migraine with signs of paralysis (cannot walk, speak or hear), dizziness, ocular and ear trouble, uses solvents (formaldehyde) at work

3 amalgams, 1st filling removed 2.96, last 2.96

2.96: less frequent migraine, continuously severe headaches

9.96: less dizziness, less severe migraine without any signs of paralysis

4.97: more frequent headaches and increased dizziness, but health improved overall

own health assessment: better

Patient No. 35 B.S., male 1957

Health Observations Before and After Amalgam Removal

symptoms: headaches, nose always stuffy (liquid secretions), sleep interruptions, bad concentration, memory loss

10 amalgams, 1st filling removed 1.96, last 4.96

1.96: severe shoulder /neck pain after first amalgam is removed

2.96: same

4.96: far better health, no headaches, more energy, even less shoulder pain, no more stuffed-up nose, better concentration

own health assessment: much better

Patient No. 36 G.K., male 1951

symptoms: migraine, strong headaches, unaccountable losses of consciousness since 1990 (resulting from whiplash injury after a head-on collision)

9 amalgams, 1st filling removed 3.96, last 8.96

8.96: significantly fewer headaches

own health assessment: much better

Patient No. 37 H.H., male 1944

symptoms: severe allergy in arms, legs and throat with danger of suffocation (always carries cortisone spray) several times a year, shoulder pain when carrying postal parcels (doctor thinks it is "wear and tear")

12 amalgams, 1st filling removed 1.94, last 12.95

1.97: allergies disappear

4.98: no more shoulder pains whatsoever

own health assessment: much better

Patient No. 41 M.W., male 1940

symptoms: severe and long-lasting migraine, dizziness, paraesthesia mainly in arms, extreme vomiting spasms, back pains, neck tension

7 amalgams, 1st filling removed 6.96, last 3.97

12.97: no migraine, paraesthesia or dizziness whatsoever, feels "reborn"

6.98: no more migraine whatsoever, feels much more stable mentally, says that neck tension and back pain have disappeared, feels "like 20" again

own health assessment: much better

Patient No. 42 H.M., female 1962

symptoms: many migraines and dizzy spells

10 amalgams, 1st filling removed 4.96, last 1.98

1.98: less migraine, dizziness gone

own health assessment: much better

Patient No. 43 R.C., female 1964

symptoms: pharyngitis, laryngitis, frequent angina, tension headaches

3 amalgams, 1st filling removed 8.96, last 10.96

1.97: less frequent but still severe headaches, pharyngitis and laryngitis improved

own health assessment: somewhat better

Patient No. 44 G.H., male 1960

symptoms: MS

10 amalgams, 1st filling removed 9.96, last 1.97

1.97: no improvement

own health assessment: worsening

Patient No. 45 C.R., male 1942

symptoms: gastro-intestinal disturbances, migraine

18 amalgams - some under crowns -, 1st filling removed 8.96, last 1.97

Health Observations Before and After Amalgam Removal

1.97: no improvement
own health assessment: worsening

Patient No. 46 S.W., male 1924
symptoms: inexplicable fatigue, diabetes
10 amalgams, 1st filling removed 6.96, last 1.97
1.97: patient feels better and has more energy
3.98: patient feels more tired
own health assessment: worsening

Patient No. 48 S.J., male 1948
symptoms: very frequent head pains, stomach trouble (acidity), skin problems, paraesthesia
15 amalgams, 1st filling removed 3.93, last 2.97
9.97: no more head pains or stomach problems
own health assessment: much better

Patient No. 49 H.R., female 1946
symptoms: headaches, migraine, dizziness, eye trouble, hand paraesthesia, neck tension, feels uneasy
12 amalgams, 1st filling removed 12.93, last 2.97
4.97: health greatly improved, hardly any migraine
8.98: migraine practically gone, health improvement “like day and night”
own health assessment: much better

Patient No. 50 S.E., female 1953
symptoms: migraine, dizziness, tensions, unaccountable strong pain in shoulder area, tennis ball-size lump (“no doctor can tell me what it is”)
13 amalgams, 1st filling removed 9.96, last 6.97
11.96: stomach / intestine much better, hardly any migraine
11.97: chest pains completely gone
7.98: further health recovery
own health assessment: much better

Patient No. 51 M.S., female 1943
symptoms: chronic colds, allergies, asthma, headaches, migraine, fatigue
3 amalgams, 1st filling removed 5.96, last 7.96
12.96: fewer colds, less asthma but continued headaches and migraine
2.97: same
own health assessment: somewhat better

Patient No. 52 S.E., female 1941
symptoms: polyarthritis, migraine (from lower rear skull and temples to behind the eyes)
5 amalgams, 1st filling removed 3.96, last 7.96
7.97: a bit less migraine, monthly instead of weekly before
1.98: same
own health assessment: somewhat better

Patient No. 53 W.L., female 1936
symptoms: headaches, allergies, sinusitis
10 amalgams, 1st filling removed 5.96, last 9.96
9.96: fewer headaches, sinusitis inflammation, but still has allergies
own health assessment: better

Patient No. 54 T.K., female 1947
symptoms: dizziness (medically diagnosed as Meniere disease), double vision, migraine,
tooth 27 removed in 11.92, less dizziness since then

Health Observations Before and After Amalgam Removal

9 amalgams, , 1st filling removed 11.92, last 10.96
7.96: less dizziness
11.97: continued recovery, practically no more dizziness
own health assessment: much better

Patient No. 55 S.H., female 1963

symptoms: migraine, sensitive to light, pressure behind eyes, nausea, gastro-intestinal disturbances, dizziness
14 amalgams, 1st filling removed 2.96, last 11.96
1.97: much less often migraine, it is more like a headache., gastro-intestinal: can once again tolerate certain food which was previously unbearable
own health assessment: much better

Patient No. 57 M.S., female 1931

symptoms: stuffy nose, allergies, inexplicable fatigue, swollen lymph glands from behind the head to throat, stomach ache, takes cortisone, eczema on hands and feet
12 amalgams, 1st filling removed 5.96, last 6.97
6.97: minimal health improvement
3.98: eczema disappeared, continued stuffy nose, continued asthma, much less tired, mentally far better off
own health assessment: much better

Patient No. 58 S.H., male 1937

symptoms: migraine, tingling in legs, tinnitus for 18 years
15 amalgams, 1st filling removed 5.95, last 10.96
1.96: migraine and paraesthesia considerably better, continued tinnitus
1.98: same
own health assessment: better

Patient No. 59 V.J., male 1944

symptoms: asthma, backache, neck tension, migraine, metal taste
5 amalgams, 1st filling removed 6.96, last 12.96
4.97: less migraine, asthma still not good
9.97: not more migraine, asthma still not good
1.98: recurrence of backache, migraine and asthma
own health assessment: somewhat better

Patient No. 60 H.S., female 1943

symptoms: MS
6 amalgams, 1st filling removed 7.94, last 6.96
3.97: no improvement
own health assessment: worsening

Patient No. 61 D.C., female 1979

symptoms: has had strong migraine with nausea for 1-2 years, 4 occlusal fillings by us 8 years before
4 amalgams, 1st filling removed 5.96, last 7.96
7.96: migraine weaker but still some dizziness
5.97: migraine and neck tension disappeared
own health assessment: much better

Patient No. 63 J.F., female 1956

symptoms: neurodermatitis (severe and painful itch on face, throat, chest and underarms (somewhat alleviated by cortisone cream)
11 amalgams, 1st filling removed 12.95, last 3.96
3.96: no more neurodermatitis

Health Observations Before and After Amalgam Removal

11.96: no more allergies

2.98: no more neurodermatitis whatsoever (cortisone discontinued over a year before)

own health assessment: much better

Patient No. 64 E.C. female 1946

symptoms: low blood pressure, headaches, frequent vocal chord troubles

8 amalgams, 1st filling removed 10.96, last 3.97

7.97: fewer headaches, continued vocal chord trouble

own health assessment: better

Patient No. 65 W.R., male 1943

symptoms: after whiplash injury concentration, memory and hearing problems, sensitive to electromagnetic fields, forced to reduce to part-time work, tinnitus, headaches, joint trouble

9 amalgams, 1st filling removed 1.97, last 4.97

4.97: generally feels better

own health assessment: much better

Patient No. 67 M.H., female 1940

symptoms: joint pains, neck tension, shoulder /arm pains

6 amalgams, 1st filling removed 7.87, last 7.87

3.97: overall health improvement

3.98: joint pains and neck tension disappeared, no more shoulder /arm pains

own health assessment: much better

Patient No. 68 H.M., male 1960

symptoms: headaches, migraine, gastro-intestinal disturbances (Crohn related?)

6 amalgams, 1st filling removed 6.96, last 1.97

2.97: no more migraine, far fewer headaches

2.98: previous migraine in 12.97 (frequent then , no more now), continued gastro-intestinal disturbances

own health assessment: much better

Patient No. 69 K.E., female 1954

symptoms: hair loss, left shoulder pain radiating to the front of the arm and chest, psychic difficulties (fear), stomach burns

15 amalgams, 1st filling removed 6.96, last 11.96

11.96: no more shoulder pain

2.97: much less hair loss

9.97: no more stomach burns, no hair loss, psychically better

own health assessment: much better

Patient No. 71 K.J., female 1935

symptoms: cardiac dysrhythmia, paraesthesia in arms and legs, dizziness, headaches

4 amalgams, 1st filling removed 4.96, last 4.96

2.97: headaches done, noticeable "hole in the head" feeling gone, paraesthesia done

3.98: continued improvement

own health assessment: much better

Patient No. 72 J.N., female 1970

symptoms: light sensitivity, ocular problems (cannot tolerate sunlight), back pains, onset of paralysis (numbness, radiating to elbows, then to shoulders, and finally knees), speech impairment severe memory loss (total loss after two minutes in remembering what she had eaten, what train she was on and in what direction)

15 amalgams, 1st filling removed 9.95, last 5.96

3.96: less dizziness, no more speech impairment, less paralysis

Health Observations Before and After Amalgam Removal

4.96: severe reaction after amalgam removal (trouble moving arm)
5.96: repeated severe reaction after amalgam removal
7.96: no more paralysis in arms, short-term memory better, when tired still problems finding words, continued severe back pains, much less sensitive to light, fewer ocular troubles, less hay fever
3.97: overall health much better
3.98: continued health improvement (“lives again”)
own health assessment: much better

Patient No. 73 V.A., female 1943

symptoms: “buzzing” in whole body, slight trembling whole body, dizziness, back tension, migraine, heart murmurs
9 amalgams, 1st filling removed 5.89, last 4.95
9.91: less dizziness and fewer heart murmurs, shorter migraine, “buzzing” in body completely disappeared
1.98: all symptoms practically gone, no more heart murmurs
own health assessment: much better

Patient No. 74 K.H., female 1930

symptoms: dizziness (medical diagnosis: Meniere disease), muscle pain, migraine, nausea
13 amalgams, 1st filling removed 11.95, last 6.96
4.96: far less dizziness and nausea
4.97: steady health improvement
own health assessment: much better

Patient No. 75 J.K., male 1937

symptoms: headaches (this his doctor believes comes from his neck vertebra), sensitivity to changes in weather
7 amalgams, 1st filling removed 7.95, last 6.97
5.97: no more sensitivity to changes in weather, no more headaches, no more dizziness
own health assessment: much better

Patient No. 76 K.B., female 1960

symptoms: allergies, fatigue, stomach /intestinal problems, sight impairment
7 amalgams, 1st filling removed 8.95, last 6.97
6.97: skin less dry, much less tired, less sight impairment, fewer gastro-intestinal disturbances, general feeling of well-being
8.98: no more sight impairment, skin and stomach much better
own health assessment: much better

Patient No. 77 F.A., female 1957

symptoms: neck tension, frequent migraine, stomach problems, hair loss, sinusitis
18 amalgams, 1st filling removed 6.95, last 8.97
8.97: much less migraine, general feeling of well-being
own health assessment: much better

Patient No. 78 F.M., female 1955

symptoms: neck tension, back pain, migraine, headaches, gastro-intestinal disturbances, mental imbalance
10 amalgams, 1st filling removed 3.97, last 10.97, possibly another amalgam under the 4 crowns
10.97: overall health improvement
1.98: continued migraine and neck tension, stomach /intestines better, depression gone, general feeling of well-being, less “fogginess” in the head, strong taste for life like before
own health assessment: much better

Patient No. 79 I.C., female 1958

Health Observations Before and After Amalgam Removal

symptoms: hayfever, neck tension, migraine
6 amalgams, 1st filling removed 12.95, last 6.96
11.96: continued severe migraine believed to be closely connected with smoking
8.97: somewhat fewer migraines, far fewer allergies, no more hay fever, neck improved
own health assessment: better

Patient No. 80 M.A., female 1938

symptoms: neck tension, migraine, headaches
13 amalgams, 1st filling removed 3.95, last 6.96
9.97: migraine disappeared, much less neck tension, only occasional headaches
7.98: further health improvement, no more neck problems (can back up while driving again), very occasional headaches, no more lower back pain at all
own health assessment: much better

Patient No. 81 H.M., female 1949

symptoms: chronic headaches, frequent numbness in right hand
15 amalgams, 1st filling removed 2.96, last 10.96
10.96: less paraesthesia in hand, far fewer headaches
1.98: headaches during menstruation, less numbness in hand, feels much better than ever before
own health assessment: much better

Patient No. 82 G.E., male 1925

symptoms: arthritis in fingers, paraesthesia
17 amalgams, 1st filling removed 3.96, last 1.98
1.98: much less arthritis in fingers, fingers much less swollen and deformed
own health assessment: much better

Patient No. 85 M.C., female 1958

symptoms: exhaustion, digestive trouble, neck tension
17 amalgams, 1st filling removed 2.96, last 7.97
5.97: strong reaction to amalgam removal (exhaustion symptoms)
7.97: same
1.98: much less neck tension, digestion improved, less exhausted, less "fogginess" in head
own health assessment: much better

Patient No. 86 M.M., female 1938

symptoms: back pains, shoulder problems (periarthritis), neck tension
13 amalgams, 1st filling removed 8.92, last 1.93
3.97: claims to feel better and to be less mentally distressed
1.98: continued back and shoulder problems, less neck tension
own health assessment: much better

Patient No. 87 S.A., female 1967

symptoms: migraine
4 amalgams, 1st filling removed 7.97, last 9.97
1.98: believes migraine to be milder and only when menstruating
own health assessment: better

Patient No. 88 R.S., female 1963

symptoms: very strong hay fever, burning sore throats, severe neck pain, shoulder pains (unable to carry handbag on shoulder), migraine
7 amalgams, 1st filling removed 1.95, last 7.96
7.96: no more migraine, less neck tension
4.98: no neck tension whatsoever, no more migraine, no more hay fever for two years, no more sore throats, no more shoulder problems
own health assessment: much better